

10-5-2021

## Intrahepatic Dynamic Contrast-Enhanced Magnetic Resonance Lymphangiography: Potential Imaging Signature for Protein-Losing Enteropathy in Congenital Heart Disease.

Bethan A Lemley

*Children's Hospital of Philadelphia, Philadelphia, PA*

David M Biko

*Children's Hospital of Philadelphia, Philadelphia, PA, bikod@chop.edu*

Aaron DeWitt

*Children's Hospital of Philadelphia, Philadelphia, PA, dewitta@chop.edu*

Andrew C Glatz

*Children's Hospital of Philadelphia, Philadelphia, PA*

David J Goldberg

*Children's Hospital of Philadelphia, Philadelphia, PA, goldbergda@chop.edu*

See this page for additional authors <https://digitalrepository.chop.edu/advpractice>



Part of the [Cardiology Commons](#), [Critical Care Commons](#), [Pediatrics Commons](#), and the [Radiology Commons](#)

---

### Citation

Lemley, B., Biko, D., DeWitt, A., Glatz, A., Goldberg, D., Saravanan, M., O'Byrne, M., Pinto, E., Ravishankar, C., Rome, J., Smith, C., & Dori, Y. (2021). Intrahepatic Dynamic Contrast-Enhanced Magnetic Resonance Lymphangiography: Potential Imaging Signature for Protein-Losing Enteropathy in Congenital Heart Disease.. *J Am Heart Assoc*, 10 (19), 021542-021542. <https://doi.org/10.1161/JAHA.121.021542>

This Article is brought to you for free and open access by the Nursing & Clinical Care Services at CHOP Digital Repository. It has been accepted for inclusion in Center for Advanced Practice by an authorized administrator of CHOP Digital Repository.




---

**Authors**

Bethan A Lemley, David M Biko, Aaron DeWitt, Andrew C Glatz, David J Goldberg, Madhumitha Saravanan, Michael L O'Byrne, Erin Pinto, Chitra Ravishankar, Jonathan Rome, Christopher L Smith, and Yoav Dori

**ORIGINAL RESEARCH**

# Intrahepatic Dynamic Contrast-Enhanced Magnetic Resonance Lymphangiography: Potential Imaging Signature for Protein-Losing Enteropathy in Congenital Heart Disease

Bethan A. Lemley , MD; Dave M. Biko, MD; Aaron G. Dewitt, MD; Andrew C. Glatz , MD, MSCE; David J. Goldberg, MD; Madhumitha Saravanan, BS; Michael L. O'Byrne, MD, MSCE; Erin Pinto, MSN, RN, CCRN, FNP-BC; Chitra Ravishankar, MD; Jonathan J. Rome, MD; Christopher L. Smith , MD, PhD; Yoav Dori, MD, PhD

**BACKGROUND:** Protein-losing enteropathy (PLE) is a significant cause of morbidity and mortality in congenital heart disease patients with single ventricle physiology. Intrahepatic dynamic contrast-enhanced magnetic resonance lymphangiography (IH-DCMRL) is a novel diagnostic technique that may be useful in characterizing pathologic abdominal lymphatic flow in the congenital heart disease population and in diagnosing PLE. The objective of this study was to characterize differences in IH-DCMRL findings in patients with single ventricle congenital heart disease with and without PLE.

**METHODS AND RESULTS:** This was a single-center retrospective study of IH-DCMRL findings and clinical data in 41 consecutive patients, 20 with PLE and 21 without PLE, with single ventricle physiology referred for lymphatic evaluation. There were 3 distinct duodenal imaging patterns by IH-DCMRL: (1) enhancement of the duodenal wall with leakage into the lumen, (2) enhancement of the duodenal wall without leakage into the lumen, and (3) no duodenal involvement. Patients with PLE were more likely to have duodenal involvement on IH-DCMRL than patients without PLE ( $P < 0.001$ ).

**CONCLUSIONS:** IH-DCMRL findings of lymphatic enhancement of the duodenal wall and leakage of lymph into the duodenal lumen are associated with PLE. IH-DCMRL is a useful new modality for characterizing pathologic abdominal lymphatic flow in PLE and might be useful as a risk-assessment tool for PLE in at-risk patients.

**Key Words:** magnetic resonance lymphangiography ■ protein-losing enteropathy ■ single ventricle heart defects ■ total cavopulmonary connection

**P**rotein-losing enteropathy (PLE) is an uncommon but worrisome complication arising in patients with single ventricle heart defects. The condition is characterized by disruption of the enteric mucosal barrier and abnormal protein loss from the lymphatic circulation via the bowel, resulting in perturbations in multiple homeostatic systems. Classically in PLE,

hypoproteinemia results in decreased vascular oncotic pressure leading to development of interstitial edema and effusions.<sup>1</sup> PLE may present with severe diarrhea, malnourishment, and ascites/effusions, or more insidiously with subtle changes in bowel habits and trace edema.<sup>1</sup> A single-center study of a large cohort of patients post total cavopulmonary connection (TCPC), the

Correspondence to: Dr Bethan Lemley, Division of Cardiology, The Children's Hospital of Philadelphia, 3401 Civic Center Blvd, 8th floor NW, Philadelphia, PA 19104. E-mail: lemleyb@chop.edu

For Sources of Funding and Disclosures, see page 8.

© 2021 The Authors. Published on behalf of the American Heart Association, Inc., by Wiley. This is an open access article under the terms of the Creative Commons Attribution-NonCommercial License, which permits use, distribution and reproduction in any medium, provided the original work is properly cited and is not used for commercial purposes.

JAHA is available at: [www.ahajournals.org/journal/jaha](http://www.ahajournals.org/journal/jaha)

## CLINICAL PERSPECTIVE

### What Is New?

- Protein-losing enteropathy is associated with significant morbidity and mortality in patients with single ventricle congenital heart disease.
- The pathophysiology of protein-losing enteropathy is not well understood.
- Intrahepatic dynamic contrast-enhanced magnetic resonance lymphangiography shows that patients with protein-losing enteropathy often have lymphatic perfusion of the duodenal wall with spillage of lymph into the bowel lumen.

### What Are the Clinical Implications?

- Intrahepatic dynamic contrast-enhanced magnetic resonance lymphangiography can guide lymphatic intervention in patients with protein-losing enteropathy.
- Intrahepatic dynamic contrast-enhanced lymphangiography may have a role in assessing the risk of protein-losing enteropathy in at-risk patients.

## Nonstandard Abbreviations and Acronyms

<b>IH-DCMRL</b>	intrahepatic dynamic contrast-enhanced magnetic resonance lymphangiography
<b>IN-DCMRL</b>	intranodal dynamic contrast-enhanced magnetic resonance lymphangiography
<b>PLE</b>	protein-losing enteropathy
<b>RV</b>	right ventricle
<b>SCPC</b>	superior cavopulmonary connection
<b>TCPC</b>	total cavopulmonary connection

Fontan operation) reported a freedom from PLE of 94% at 10 years and 88% at 20 years,<sup>2</sup> although given what is known about the clinical spectrum of the presentation, it is possible that these are underestimates of the true PLE prevalence in the single ventricle population.

While improvements in supportive care and treatment options have led to an improvement in the 5-year survival from 46% to 88%, mortality associated with PLE after TCPC remains high, and long-term outcomes are poor.<sup>3,4</sup> Although our understanding of PLE has evolved, the residual morbidity and mortality burden likely reflects gaps in the current understanding of the pathophysiology of PLE. Current evidence suggests that development of PLE is related to elevated central venous pressure that results

in lymphatic congestion due to both increased lymph production and relative flow obstruction at the drainage point of the thoracic duct into the venous system. It is hypothesized that the congested lymphatic system develops fistulous connections with the bowel allowing for lymphatic decompression but resulting in protein loss and the development of clinical PLE. However, not all patients with elevated central venous pressure across their TCPC develop PLE, suggesting there is more to the relationship between PLE and the lymphatic system than has been thus far elucidated.<sup>5</sup>

Historically there has been no role for lymphatic imaging in evaluating PLE. Conventional lymphangiography is the primary modality for lymphatic intervention but has had limited diagnostic utility when it comes to evaluating and understanding more global lymphatic pathology. Conventional lymphangiography is 2-dimensional. It provides no contextual information regarding neighboring soft-tissue structures and inadequate delineation of downstream lymphatic structures due to restricted distribution of water-soluble contrast.<sup>6</sup> Dynamic contrast-enhanced magnetic resonance lymphangiography (DCMRL) was developed to overcome these limitations. DCMRL is a 3-dimensional imaging modality that offers excellent spatial and temporal resolution of the lymphatic system and surrounding structures.

We have previously reported on the role of DCMRL in imaging the central lymphatic system.<sup>7</sup> Intranodal DCMRL (IN-DCMRL), in which MR lymphangiography is performed after contrast agent is administered via inguinal lymph node access, has become a routine part of the diagnostic evaluation of patients with plastic bronchitis or chylous pleural or pericardial effusions in our center.<sup>8-10</sup> In addition to delineating pathologic thoracic lymphatic flow patterns, IN-DCMRL has proven useful in guiding lymphatic interventions.<sup>9,11</sup> However, the hepatic lymphatic network implicated in the pathophysiology of PLE is not well-visualized by IN-DCMRL as hepatic lymphatics are upstream of the cisterna chyli and do not enhance when contrast is administered via inguinal lymph node access.

Intrahepatic DCMRL (IH-DCMRL) in which contrast agent is administered into peri-portal lymphatic channels, was developed to visualize hepatic lymphatic pathology with the goal of guiding intervention in PLE.<sup>6</sup> In this study, we present findings of IH-DCMRL in patients with single ventricle physiology referred for lymphatic evaluation. Our primary aim was to compare the IH-DCMRL findings of patients with PLE to those without PLE. Additionally, we characterized the differences in imaging patterns in these patients and explored the potential role of IH-DCMRL in the evaluation of patients at risk for PLE.

## METHODS

### Study Design and Population

This is a cross-sectional study with retrospective data collection of consecutive patients with single ventricle heart disease (shunt-dependent or post-superior or total cavopulmonary connections) who underwent IH-DCMRL as part of a standard, comprehensive, lymphatic evaluation at the Center for Lymphatic Disorders at the Children's Hospital of Philadelphia between February 2018 and August 2019. Demographics, diagnoses, laboratory data, and echocardiographic and catheterization parameters were extracted from the electronic medical records. This study was approved by The Children's Hospital of Philadelphia Institutional Review Board. Informed consent was waived. The data that supports the findings of this study are available from the corresponding author upon reasonable request.

### Intrahepatic Dynamic Contrast-Enhanced MR Lymphangiography

IH-DCMRL studies were performed in a hybrid catheterization-magnetic resonance imaging laboratory. Lymphatic access was obtained in the cardiac catheterization laboratory under general anesthesia by a dedicated team of interventional cardiologists. More detailed technique was described elsewhere but briefly in all patients the hepatic lymphatic system was accessed under ultrasound guidance using a 3.5 inch 25-gauge spinal needle that was positioned near a branch of the portal system and position was confirmed by fluoroscopy using a water-soluble contrast agent.<sup>6</sup> These patients also underwent intranodal lymphatic access. Access was secured with adhesives and the patients were transferred to an adjacent MRI suite.

MRIs were performed with a 1.5-T magnet (Siemens Healthineers MAGNETOM Avanto) using undiluted gadobutrol (Gadavist, Bayer Healthcare) at a dose of 0.1–0.2 mmol/kg injected by hand at an approximate rate of 1–2 mL/min, as a contrast agent.<sup>6</sup> After injection of contrast, time-resolved imaging with interleaved stochastic trajectories (TWIST) with temporal resolution of 8–12 seconds was performed over 6–7 minutes and high-resolution respiratory-navigated 3D IR T1 gradient echo sequences over 2–5 minutes were performed as previously described.<sup>6</sup>

Imaging analysis was done by a team of pediatric radiologists trained in lymphatic imaging. MRI reports were reviewed for qualitative descriptions of abdominal lymphatic findings. In the case of incomplete or unclear reports, imaging was directly reviewed by a senior member of the lymphatic disorders team (YD). Three

categories of lymphatic imaging results were defined as described below.

### Statistical Analysis

PLE and other lymphatic diagnoses were extracted from the intake letter generated at the time of each subjects' referral to the Center for Lymphatic Disorders and were made by the patients' treating cardiologists. The method of PLE diagnosis was not independently reviewed for the purposes of this study but all patients in the PLE group had hypoalbuminemia. Patients in the PLE cohort included subjects with and without other concomitant lymphatic disorders. Descriptive statistics were calculated for the PLE and no-PLE cohorts to demonstrate the comparability of the 2 cohorts. Continuous variables were expressed as median (interquartile range). Categorical variables were expressed as count (percent). Wilcoxon rank sum and Fisher's exact tests were used to evaluate the differences between the 2 cohorts. An alpha level of 0.05 was considered statistically significant.

The primary aim of the study was to evaluate the differences in IH-DCMRL imaging patterns in the PLE and no-PLE patients. A Fisher's exact test was used to evaluate the difference in distributions of patterns between the cohorts. A Fisher's exact test was also used in a sub-analysis of subjects who were post-TCPC. All analyses were performed using STATA 16.1 (Statacorp, College Station, TX).

## RESULTS

Twenty patients with a diagnosis of PLE and 21 patients with no PLE diagnosis who were referred for other lymphatic disorders, were included. Thirteen of the patients had multiple lymphatic disorders, such as plastic bronchitis and pleural effusions. Plastic bronchitis and pleural effusion were the most common lymphatic diagnoses represented in the no-PLE cohort (Table).

The PLE cohort was significantly older than the no-PLE cohort, with a median age of 14.2 years compared to 5.3 years, respectively ( $P < 0.001$ ). The patients in the PLE cohort had all undergone TCPC. This differed significantly from the distribution of surgical stages in the no-PLE group ( $P = 0.02$ ). In the no-PLE group, 15 patients were post TCPC, 4 patients were post-superior cavopulmonary connection (SCPC), and 2 patients were pre-SCPC. The 2 groups had a similar distribution of underlying cardiac diagnoses ( $P = 0.14$ ); approximately a third of the patients in each group had hypoplastic left heart syndrome.

The majority of patients in both groups had normal or mildly diminished systolic function by echo, with no

**Table. Demographics and Clinical Characteristics of PLE and no-PLE Cohorts**

	No PLE (N=21)	PLE (N=20)	Total (N=41)	P value
Age, y	5.3 (3.7–7.6)	14.2 (7.2–18.5)	7.6 (4.9–13.8)	<0.001
Height, cm	102.0 (90.0–112.0)	141.5 (121.5–162.0)	120.0 (101.0–142.0)	<0.001
Weight, kg	14.9 (11.0–21.7)	41.2 (23.4–53.6)	21.7 (14.8–41.9)	<0.001
Female	9 (42.9%)	8 (40.0%)	17 (41.5%)	>0.999
Systemic RV	14 (66.7%)	13 (65.0%)	27 (65.9%)	>0.999
Heterotaxy	7 (33.3%)	5 (25.0%)	12 (29.3%)	0.73
Cardiac diagnosis				0.14
HLHS	7 (33.3%)	7 (35.0%)	14 (34.1%)	
Other	3 (14.3%)	9 (45.0%)	12 (29.3%)	
PA/IVS	1 (4.8%)	0 (0.0%)	1 (2.4%)	
Tricuspid Atresia	4 (19.0%)	2 (10.0%)	6 (14.6%)	
Unbalanced Canal	6 (28.6%)	2 (10.0%)	8 (19.5%)	
Surgical stage				0.02
pre-SCPC	2 (9.5%)	0 (0.0%)	2 (4.9%)	
post-SCPC	4 (19.0%)	0 (0.0%)	4 (9.8%)	
post-TCPC	15 (71.4%)	20 (100.0%)	35 (85.4%)	
Albumin (prior to IH-DCMRL)	3.8 (3.4–4.8)	3.0 (2.2–4.0)	3.5 (2.8–4.2)	0.002
Albumin (minimum)	3.0 (2.2–3.6)	2.3 (1.9–2.8)	2.5 (2.1–3.1)	0.03
Normal/mildly diminished function by echo	18 (85.7%)	17 (85.0%)	35 (85.4%)	>0.999
Enteral budesonide	1 (4.8%)	14 (70.0%)	15 (36.6%)	<0.001
Lymphatic diagnoses				
Plastic bronchitis	11 (52.4%)	3 (15.0%)	14 (34.1%)	0.02
Pleural effusion	13 (61.9%)	5 (25.0%)	18 (43.9%)	0.03
Pericardial effusion	1 (4.8%)	0 (0.0%)	1 (2.4%)	>0.999
Ascites	1 (4.8%)	1 (5.0%)	2 (4.9%)	>0.999
	No PLE (N=15)	PLE (N=20)		
Central venous pressure (mm Hg)*	15.0 (13.0–16.0)	17.8 (13.5–19.3)	15.5 (13.5–18.0)	0.1

Continuous variables are expressed as median (interquartile range). Categorical variables are expressed as count (percentage). HLHS indicates hypoplastic left heart syndrome; IH-DCMRL, intrahepatic dynamic contrast-enhanced magnetic resonance lymphangiography; PA/IVS, pulmonary atresia/intact ventricular septum; PLE indicates protein-losing enteropathy; RV, right ventricle; SCPC, superior cavopulmonary connection; and TCPC, total cavopulmonary connection.

\*Central venous pressure measurements included only patients who were post-total cavopulmonary connection.

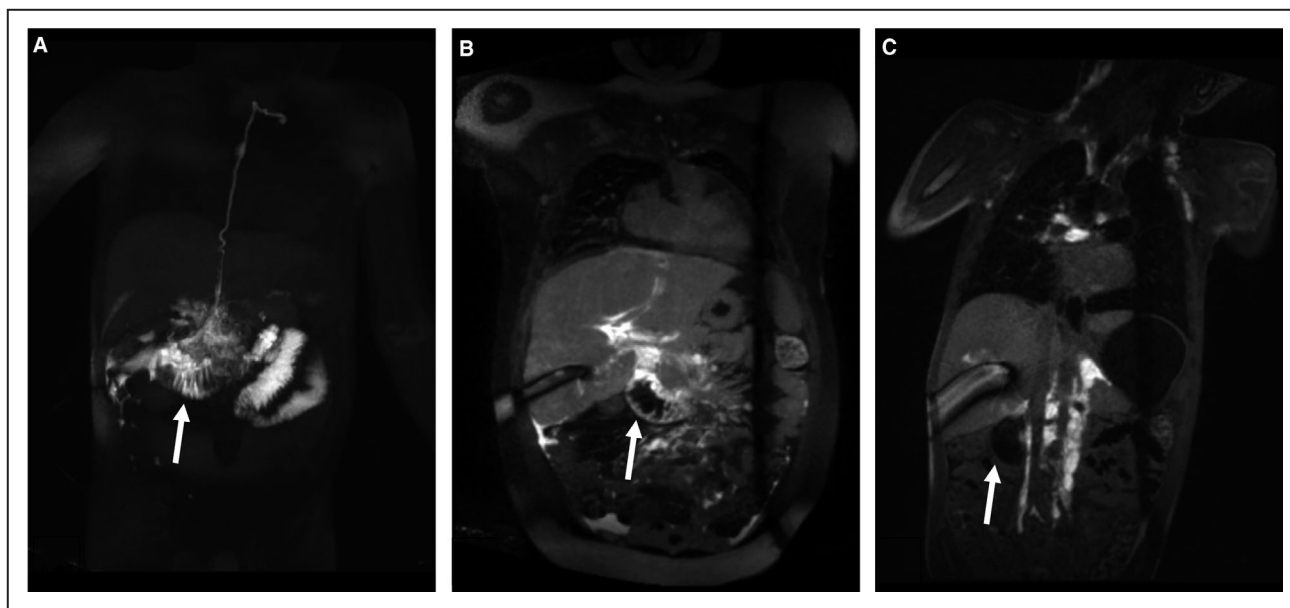
significant difference between groups ( $P>0.999$ ). In patients post-TCPC, there was no significant difference between the patients' central venous pressures measured at the time of IH-DCMRL between the PLE and no-PLE cohorts ( $P=0.1$ ).

As expected, the PLE patients had significantly lower albumin levels than the patients with no PLE, with a median albumin prior to IH-DCMRL of 3.0 g/dL and 3.8 g/dL ( $P=0.002$ ), respectively, and a median minimum albumin of 2.3 g/dL and 3.0 g/dL, respectively ( $P=0.03$ ). More of the patients in the PLE cohort (70%) were on enteral budesonide at the time of IH-DCMRL than in the no-PLE group ( $P<0.001$ ). Of those in the PLE cohort not on enteral budesonide at the time of IH-DCMRL, all but 1 patient had previously trialed enteral budesonide and reportedly discontinued it due to inefficacy or intolerable side effects. One patient in the no-PLE cohort was on enteral budesonide at the time

of IH-DCMRL. The patient had plastic bronchitis and had no history of a PLE diagnosis.

## Imaging Findings

IH-DCMRL was notable for 3 distinct lymphatic imaging patterns with a spectrum of small bowel involvement: (1) Contrast enhancement of the duodenal wall with contrast leaking into the duodenal lumen, (2) contrast enhancement of the duodenal wall without leakage into the duodenal lumen, and (3) no contrast enhancement of the duodenal wall or leakage into the lumen (Figure 1). There was no enhancement of any other portions of the small bowel wall by IH-DCMRL. Eighty-five percent of the PLE cohort and 5% of the no-PLE cohort had enhancement of the duodenal wall with leakage into the lumen. Fifteen percent of the PLE cohort and 10% of the no-PLE cohort had enhancement of the duodenal



**Figure 1.** Intrahepatic dynamic contrast-enhanced magnetic resonance lymphangiography coronal sections in single ventricle heart disease patients.

**A**, Duodenal wall enhancement and leakage of contrast into the bowel lumen (arrow) in a patient with PLE. Contrast distribution subsequently visualized throughout bowel. **B**, Duodenal wall enhancement without leakage of contrast into the bowel lumen (arrow) in a patient with PLE. **C**, No duodenal wall enhancement or leakage into the bowel lumen (arrow) in a patient without PLE. PLE indicates protein-losing enteropathy.

wall without leakage into the lumen. And none of the PLE cohort and 86% of the no-PLE cohort had no duodenal involvement. The difference in the distributions of imaging patterns between the PLE and no-PLE cohorts was statistically significant ( $P < 0.001$ ) (Figure 2A).

A sub-analysis of the IH-DCMRL findings restricted to the patients who were post-TCPC was performed (Figure 2B). When patients who had not undergone TCPC were excluded, there remained 20 patients in the PLE group and 16 patients in the no-PLE group. A statistically significant difference between the distribution of imaging patterns in the PLE versus no-PLE groups persisted ( $P < 0.001$ ).

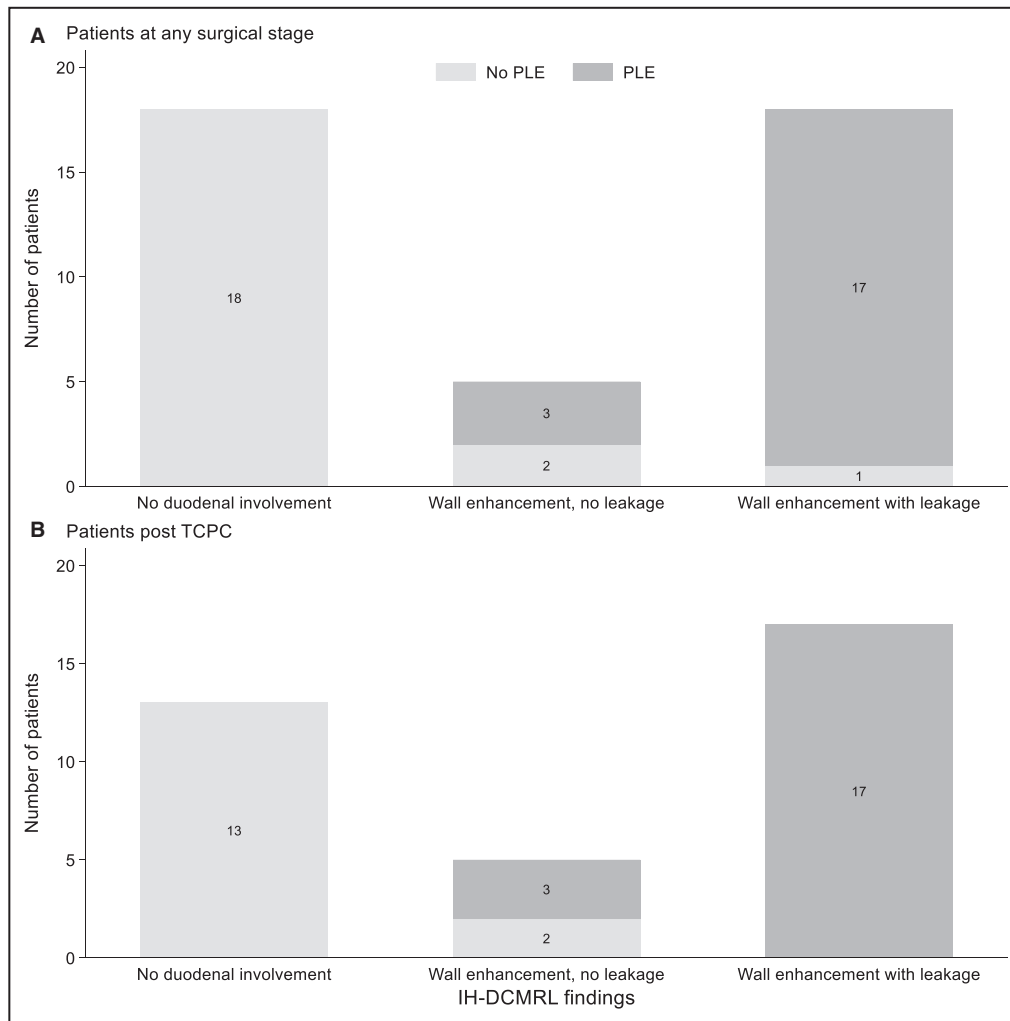
Notably, 3 patients in the no-PLE cohort had duodenal involvement as seen by IH-DCMRL. Two of these patients had duodenal wall enhancement without leakage into the lumen and one had duodenal wall enhancement with leakage into the lumen. Of the patients without luminal leakage, one was a 3-year-old with hypoplastic left heart syndrome post-TCPC with chylous pleural effusions, and the other patient was a 5-year-old with hypoplastic left heart syndrome post TCPC with plastic bronchitis. Interestingly, the 5-year-old with plastic bronchitis was diagnosed with PLE within 2 months of undergoing IH-DCMRL. The 3-year-old with chylous pleural effusions had a screening stool alpha-1-antitrypsin which was noted retrospectively to be at the high range of normal. The third patient without a PLE diagnosis who had duodenal involvement was a 5-month-old with hypoplastic

left heart and bidirectional Glenn, with chylous pleural effusions. This patient's imaging was challenging to interpret due to the patient's small size, however, review of the IH-DCMRL imaging was notable for duodenal wall enhancement with a small amount of leakage into the bowel lumen. Notably, all 3 of these patients had low minimum albumin levels, ranging from 2.0 to 2.7 g/dL.

There were 3 patients with PLE who had duodenal wall enhancement but no clear leakage of contrast into the small bowel lumen by IH-DCMRL.

## DISCUSSION

The pathophysiology of PLE is likely multifactorial with inflammatory, physiologic, and anatomic factors contributing to increased enteric protein loss and decreased vascular oncotic pressure.<sup>5,12–14</sup> Therapeutic approaches have generally targeted hypoproteinaemia, the diminished integrity of intestinal mucosa, and underlying altered hemodynamics.<sup>12</sup> Treatment options can also be classified as medical therapies (diuretics, afterload reducers, inotropes, pulmonary vasodilators, aldosterone antagonists, and steroids), nutritional strategies (protein and triglyceride-rich diet and albumin infusions), and invasive catheter-based interventions or surgical revisions.<sup>5,12</sup> However, none of these therapies have dramatically altered the average PLE prognosis. A large multicenter study of Fontan patients with PLE demonstrated



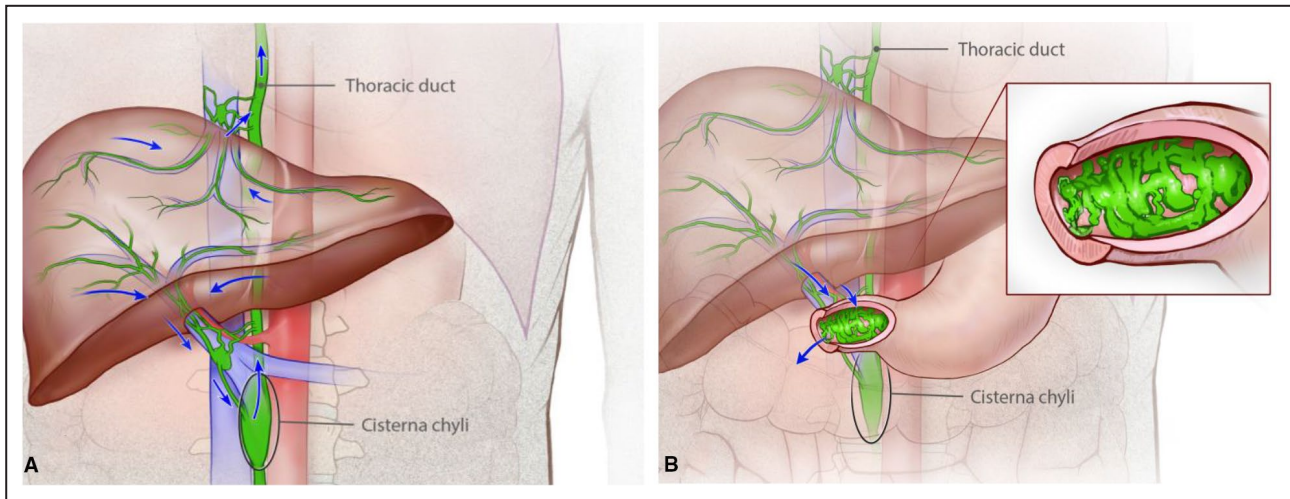
**Figure 2.** Distributions of IH-DCMRL imaging patterns (duodenal wall enhancement with leakage into the bowel lumen, duodenal wall enhancement with no leakage into the bowel lumen, and no duodenal involvement) were significantly different between the PLE patients and the no-PLE patients.

**A**, Patients at any surgical stage ( $P < 0.001$ ) (**B**) patients post TCPC ( $P < 0.001$ ). Bars are labeled with counts. IH-DCMRL indicates intrahepatic dynamic contrast-enhanced magnetic resonance lymphangiography; PLE, protein-losing enteropathy; and TCPC, total cavopulmonary connection.

that traditional treatment strategies have resulted in symptomatic improvement in only modest proportions of patients and mortality remains high even with treatment.<sup>5</sup> Small series specifically evaluating the utility of oral budesonide, a mainstay in treatment of PLE, have demonstrated some improvement in lab abnormalities but limited improvement in symptoms and outcome with significant steroid-related side effects.<sup>15–17</sup> And evidence suggests that the only truly effective treatment strategy for PLE is heart transplant.<sup>18–22</sup> The suboptimal response of Fontan patients with PLE to common therapies strongly suggests that there are pathophysiologic mechanisms underlying PLE that are not addressed by current common treatment regimens.

There is growing evidence implicating lymphatic system dysfunction in the development of PLE and our results further support this hypothesis. Generally, lymph from the hepatic lymphatic network flows to the cisterna chyli, up the thoracic duct, and drains into the systemic venous circulation (Figure 3A). We suspect in PLE there is a degree of abnormal retrograde flow of lymph from the hepatic lymphatic network to the duodenal wall. This can cause dilation of lacteals in the duodenal wall and eventual rupture and leakage of lymph into the duodenal lumen (Figure 3B). Previously intestinal lymphangiectasia has been described on pathology specimens from endoscopic bowel biopsies in PLE patients.<sup>3,23</sup> In 2 small series of congenital heart disease patients with PLE, abnormal





**Figure 3.** Diagram of the normal hepatic lymphatic networks showing flow from the liver towards the cisterna chyli and into the thoracic duct (A) and hepatic lymphatic flow in PLE showing hepatoduodenal connections to the proximal duodenum (B). Inset: Dilated lacteals in the duodenal wall are prone to rupture, spilling lymph into the bowel lumen. PLE indicates protein-losing enteropathy.

retrograde hepatoduodenal lymphatic flow has been demonstrated.<sup>24,25</sup> In one of these studies, blue dye injected into hepatic lymphatic networks could be seen endoscopically, leaking from the wall of the duodenum into the duodenal lumen.<sup>24</sup> Embolization of hepatoduodenal lymphatic connections has resulted in increased albumin levels and modest improvements in PLE symptoms in some patients, supporting the hypothesis that hepatoduodenal connections contribute to clinical PLE.<sup>24,25</sup>

In this study, patients with PLE universally had duodenal involvement as seen by IH-DCMRL. Instead of draining to the cisterna chyli, some of the contrast injected into the hepatic lymphatic network flowed retrograde causing duodenal wall enhancement. And in most cases of patients with PLE, there was leakage of contrast into the duodenal lumen. In contrast, most of the patients without PLE had no enhancement of the duodenal wall or leakage into the lumen on IH-DCMRL. Of the 3 patients without a diagnosis of PLE who had duodenal involvement on IH-DCMRL, one of these patients developed PLE within months of imaging. Such patients may represent a cohort of patients at-risk for PLE or a cohort with pre-symptomatic PLE who may soon progress to clinical PLE. We do not universally collect stool alpha-1 antitrypsin levels on all patients referred for lymphatic evaluation, and therefore do not know if these individuals would have met diagnostic criteria for PLE at the time of IH-DCMRL.

IH-DCMRL findings of duodenal wall enhancement and leakage of contrast into the duodenal lumen represent a novel imaging signature for PLE with important potential applications. At our institution

IH-DCMRL is performed in all patients referred for lymphatic evaluation and results directly inform subsequent lymphatic interventions. In this study there were no complications from the IH-DCMRL procedure. However, possible complications including bleeding and infection could occur. In using a more invasive procedure as a screening tool the risk and benefit of the procedure needs to be considered and should be studied.

In PLE patients, IH-DCMRL findings of duodenal involvement typically lead to intervention, most often embolization of hepatoduodenal lymphatic channels. Additionally, we propose that IH-DCMRL may have a role in assessing for duodenal involvement in populations at high-risk for PLE, such as those post-TCP with other lymphatic diagnoses. Duodenal involvement observed in this population could alter management. Just as T2-weighted MRI evaluation of lymphatic anatomy pre-TCP has proven useful in predicting post-operative clinical outcomes,<sup>26,27</sup> IH-DCMRL could potentially be a useful modality for pre-operative risk-assessment for developing PLE post-TCP.

In this study the PLE cohort was older and more likely to have undergone TCP than the no-PLE cohort. To evaluate whether duodenal involvement on IH-DCMRL was associated with PLE versus simply post-TCP status, a sub-analysis restricting to patients post-TCP was undertaken. In this analysis, there remained a statistically significant association between duodenal involvement on IH-DCMRL and PLE diagnosis, making it unlikely that surgical stage alone was responsible for the association between PLE and findings of duodenal involvement by IH-DCMRL.

## Limitations

Due in part to the small size of the lymphatics team and the retrospective nature of the study, the radiologists reading the IH-DCMRL studies were unblinded to the patient's lymphatic diagnoses, which could be a source of potential bias. However, all IH-DCMRL studies were interpreted by a radiologist as well as an interventional cardiologist at the time of the study and all inconsistencies in reporting were reviewed by a senior member of the lymphatics team at the time of this study, mitigating this potential source of bias.

There was limited clinical and diagnostic information in records for patients from outside centers referred to our center for lymphatics evaluation regarding PLE diagnosis and duration and course of illness. Thus, we were not able to independently validate PLE diagnoses and were not able to correlate IH-DCMRL findings to PLE activity and severity. Generally, the patients referred for lymphatic evaluation had severe symptoms that had been refractory to standard treatment which may limit the generalizability of our findings to patients with less severe PLE symptoms. Future work may further address this limitation.

## CONCLUSIONS

IH-DCMRL is a moderately invasive imaging modality that is useful for characterizing abnormal lymphatic flow in patients with PLE. Patients with PLE were more likely than those without PLE to have duodenal wall enhancement and leakage of contrast into the duodenal lumen. These IH-DCMRL findings represent a novel imaging signature for PLE. IH-DCMRL informs lymphatic interventions and may be useful for assessing risk for PLE in at-risk populations.

## ARTICLE INFORMATION

Received March 6, 2021; accepted July 20, 2021.

### Affiliations

Division of Cardiology (B.A.L., A.C.G., D.J.G., M.S., M.L.O., E.P., C.R., J.J.R., C.L.S., Y.D.), Department of Pediatrics, Perelman School of Medicine, University of Pennsylvania (B.A.L., A.G.D., A.C.G., D.J.G., M.S., M.L.O., E.P., C.R., J.J.R., C.L.S., Y.D.); Department of Radiology (D.M.B.); Department of Radiology, Perelman School of Medicine, University of Pennsylvania, Philadelphia, PA (D.M.B.); and Division of Critical Care, The Children's Hospital of Philadelphia, Philadelphia, PA (A.G.D.).

### Sources of Funding

Dr Lemley and Dr O'Byrne received support from the National Institutes of Health/National Heart, Lung, and Blood Institute (T32-HL007915 and K23 HL 130420-01, respectively). The funding agencies had no role in the planning or execution of the study, nor did they edit the manuscript. The manuscript represents the opinions of the authors alone.

### Disclosures

Dr Ravishankar has participated in advisory boards on nutrition for Nutricia. The remaining authors have no disclosures to report.

## REFERENCES

- Goldberg DJ, Dodds K, Rychik J. Rare problems associated with the Fontan circulation. *Cardiol Young*. 2010;20:113–119. DOI: 10.1017/S1047951110001162.
- Allen KY, Downing TE, Glatz AC, Rogers LS, Ravishankar C, Rychik J, Fuller S, Montenegro LM, Steven JM, Spray TL, et al. Effect of Fontan-associated morbidities on survival with intact Fontan circulation. *Am J Cardiol*. 2017;119:1866–1871. DOI: 10.1016/j.amjcard.2017.03.004.
- Feldt RH, Driscoll DJ, Offord KP, Cha RH, Perrault J, Schaff HV, Puga FJ, Danielson GK. Protein-losing enteropathy after the Fontan operation. *J Thorac Cardiovasc Surg*. 1996;112:672–680. DOI: 10.1016/S0022-5223(96)70051-X.
- John AS, Johnson JA, Khan M, Driscoll DJ, Warnes CA, Cetta F. Clinical outcomes and improved survival in patients with protein-losing enteropathy after the Fontan operation. *J Am Coll Cardiol*. 2014;64:54–62. DOI: 10.1016/j.jacc.2014.04.025.
- Mertens L, Hagler DJ, Sauer U, Somerville J, Gewillig M. Protein-losing enteropathy after the Fontan operation: an international multicenter study. *J Thorac Cardiovasc Surg*. 1998;115:1063–1073. DOI: 10.1016/S0022-5223(98)70406-4.
- Biko DM, Smith CL, Otero HJ, Saul D, White AM, DeWitt A, Glatz AC, Piccoli DA, Mamula P, Rome JJ, et al. Intrahepatic dynamic contrast MR lymphangiography: initial experience with a new technique for the assessment of liver lymphatics. *Eur Radiol*. 2019;29:5190–5196. DOI: 10.1007/s00330-019-06112-z.
- Dori Y. Novel lymphatic imaging techniques. *Tech Vasc Interv Radiol*. 2016;19:255–261. DOI: 10.1053/j.tvir.2016.10.002.
- Savla JJ, Itkin M, Rossano JW, Dori Y. Post-operative chylothorax in patients with congenital heart disease. *J Am Coll Cardiol*. 2017;69:2410–2422. DOI: 10.1016/j.jacc.2017.03.021.
- Dori Y, Keller MS, Rome JJ, Gillespie MJ, Glatz AC, Dodds K, Goldberg DJ, Goldfarb S, Rychik J, Itkin M. Percutaneous lymphatic embolization of abnormal pulmonary lymphatic flow as treatment of plastic bronchitis in patients with congenital heart disease. *Circulation*. 2016;133:1160–1170. DOI: 10.1161/CIRCULATIONAHA.115.019710.
- Dori Y, Zviman MM, Itkin M. Dynamic contrast-enhanced MR lymphangiography: feasibility study in swine. *Radiology*. 2014;273:410–416. DOI: 10.1148/radiol.14132616.
- Dori Y, Keller MS, Rychik J, Itkin M. Successful treatment of plastic bronchitis by selective lymphatic embolization in a Fontan patient. *Pediatrics*. 2014;134:e590–e595. DOI: 10.1542/peds.2013-3723.
- Rychik J, Spray TL. Strategies to treat protein-losing enteropathy. *Pediatr Card Surg Annu*. 2002;5:3–11. DOI: 10.1053/pcsu.2002.31498.
- Johnson JN, Driscoll DJ, O'Leary PW. Protein-losing enteropathy and the Fontan operation. *Nutr Clin Pract*. 2012;27:375–384. DOI: 10.1177/0884533612444532.
- Braamskamp MJAM, Dolman KM, Tabbers MM. Clinical practice: protein-losing enteropathy in children. *Eur J Pediatr*. 2010;169:1179–1185. DOI: 10.1007/s00431-010-1235-2.
- John AS, Driscoll DJ, Warnes CA, Phillips SD, Cetta F. The use of oral budesonide in adolescents and adults with protein-losing enteropathy after the Fontan operation. *Ann Thorac Surg*. 2011;92:1451–1456. DOI: 10.1016/j.athoracsur.2011.03.103.
- Schumacher KR, Cools M, Goldstein BH, Ioffe-Dahan V, King K, Gaffney D, Russell MW. Oral budesonide treatment for protein-losing enteropathy in Fontan-palliated patients. *Pediatr Cardiol*. 2011;32:966–971. DOI: 10.1007/s00246-011-0029-2.
- Thacker D, Patel A, Dodds K, Goldberg DJ, Semeao E, Rychik J. Use of oral budesonide in the management of protein-losing enteropathy after the Fontan operation. *Ann Thorac Surg*. 2010;89:837–842. DOI: 10.1016/j.athoracsur.2009.09.063.
- Kanter KR. Heart transplantation in children after a Fontan procedure: better than people think. *Semin Thorac Cardiovasc Surg Pediatr Card Surg Ann*. 2015;19:44–49. DOI: 10.1053/j.pcsu.2015.11.004.
- Jayakumar KA, Addonizio LJ, Kichuk-Chrisant MR, Galantowicz ME, Lamour JM, Quaegebeur JM, Hsu DT. Cardiac transplantation after the Fontan or Glenn procedure. *J Am Coll Cardiol*. 2004;44:2065–2072. DOI: 10.1016/j.jacc.2004.08.031.
- Gamba A, Merlo M, Fiocchi R, Terzi A, Mammanna C, Sebastiani R, Ferrazzi P. Heart transplantation in patients with previous Fontan operations. *J Thorac Cardiovasc Surg*. 2004;127:555–562. DOI: 10.1016/j.jtcvs.2003.08.016.

21. Davies RR, Sorabella RA, Yang J, Mosca RS, Chen JM, Quaegebeur JM. Outcomes after transplantation for “failed” Fontan: a single-institution experience. *J Thorac Cardiovasc Surg.* 2012;143:1183–1192. e4. DOI: 10.1016/j.jtcvs.2011.12.039.
22. Backer CL, Russell HM, Pahl E, Mongé MC, Gambetta K, Kindel SJ, Gossett JG, Hardy C, Costello JM, Deal BJ. Heart transplantation for the failing Fontan. *Ann Thorac Surg.* 2013;96:1413–1419. DOI: 10.1016/j.athoracsur.2013.05.087.
23. Connor FL, Angelides S, Gibson M, Larden DW, Roman MR, Jones O, Currie BG, Day AS, Bohane TD. Successful resection of localized intestinal lymphangiectasia post-Fontan: role of (99m)technetium-dextran scintigraphy. *Pediatrics.* 2003;112:242–247. DOI: 10.1542/peds.112.3.e242.
24. Itkin M, Piccoli DA, Nadolski G, Rychik J, Dewitt A, Pinto E, Rome J, Dori Y. Protein-losing enteropathy in patients with congenital heart disease. *J Am Coll Cardiol.* 2017;69:2929–2937. DOI: 10.1016/j.jacc.2017.04.023.
25. Maleux G, Storme E, Cools B, Heying R, Boshoff D, Louw JJ, Frerich S, Malekzadeh-Milani S, Hubrechts J, Brown SC, et al. Percutaneous embolization of lymphatic fistulae as treatment for protein-losing enteropathy and plastic bronchitis in patients with failing Fontan circulation. *Catheter Cardiovasc Interv.* 2019;94:996–1002. DOI: 10.1002/ccd.28501.
26. Biko DM, DeWitt AG, Pinto EM, Morrison RE, Johnstone JA, Griffis H, O’Byrne ML, Fogel MA, Harris MA, Partington SL, et al. MRI evaluation of lymphatic abnormalities in the neck and thorax after Fontan surgery: relationship with outcome. *Radiology.* 2019;291:774–780. DOI: 10.1148/radiol.2019180877.
27. Ghosh RM, Griffis HM, Glatz AC, Rome JJ, Smith CL, Gillespie MJ, Whitehead KK, O’Byrne ML, Biko DM, Ravishankar C, et al. Prevalence and cause of early Fontan complications: does the lymphatic circulation play a role? *J Am Heart Assoc.* 2020;9:e015318. DOI: 10.1161/JAHA.119.015318.